Center for Structural Heart Disease

From Research to Recovery

ACTIVITY AND OUTCOMES 2017

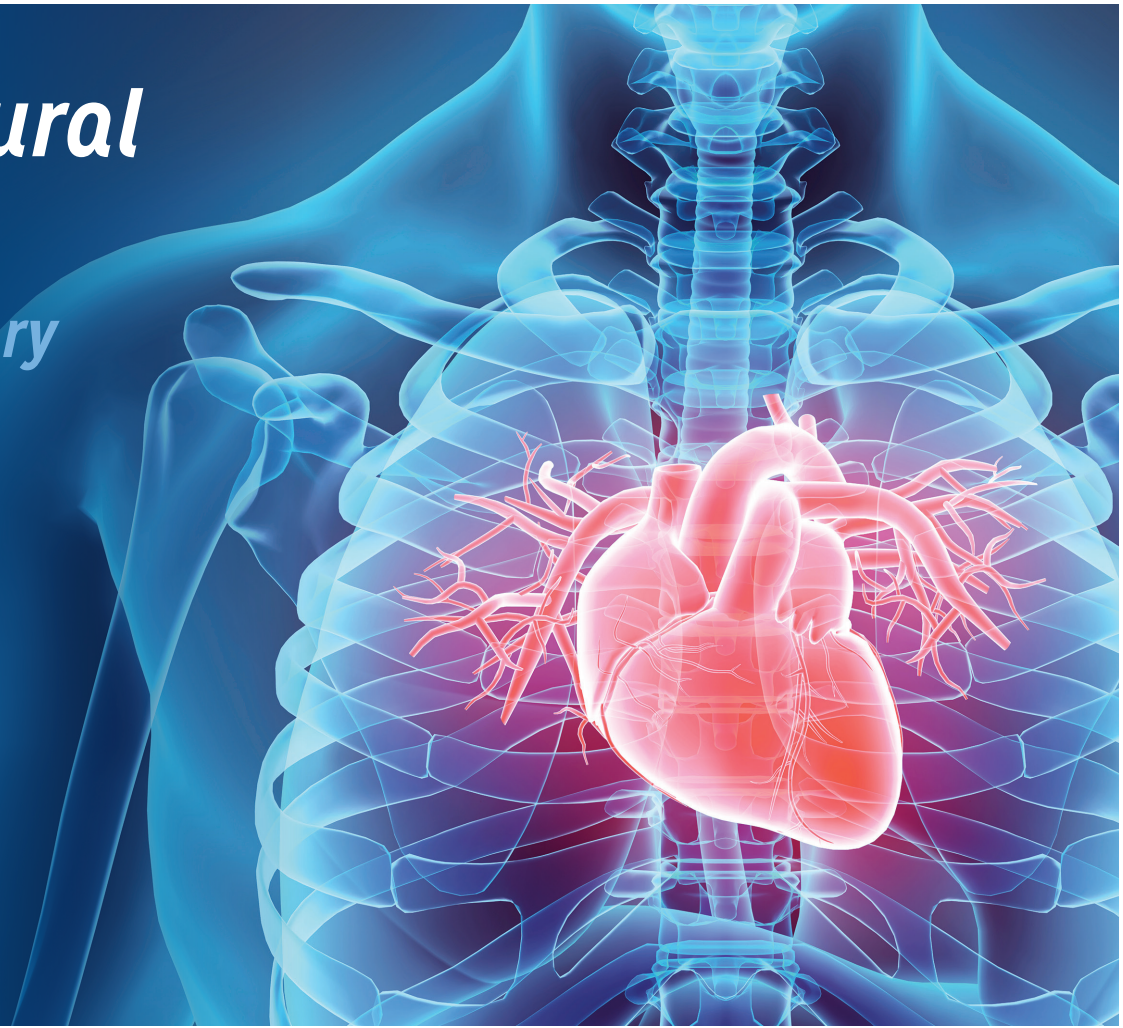

Henry Ford Health System®

HENRY FORD HOSPITAL

Center for Structural Heart Disease Team

FROM THE DESK OF WILLIAM W. O'NEILL, M.D.

William W. O'Neill, M.D.
Medical Director
Twitter: @BillONeillMD

The Center for Structural Heart Disease team is known for their hard work and clinical innovations. It is late night brainstorming sessions and ongoing clinical research that continues to result in innovative treatment options – all with the hope of saving lives of patients who have little or no other options. Achieving a milestone, 90-year-old Jerry Licht became the 1000th TAVR patient, who trusted we'd get him back to traveling and walking his dog.

Innovation continues in the advancement of approaches in TAVR procedures. While transfemoral remains the most frequent approach, Adam Greenbaum, M.D., co-director, Center for Structural Heart Disease, has advanced transcaval, and Gaetano Paone, M.D., division head of Cardiac Surgery has advanced the transcarotid approach.

The work of Dee Dee Wang, M.D., director, Structural Heart Imaging, in 3D Imaging and printing technology has shown extraordinary results in safety and efficacy. Through pre- and post-procedure planning, her work in prediction modeling has gained national attention. We are grateful for the collaboration with Henry Ford cardiologists who have embraced 3D and guide imaging technology.

Marvin Eng, M.D., research director, Center for Structural Heart Disease, has established the largest mitral valve portfolio of devices for mitral and heart valve repair and replacement. We believe this portfolio to be one of the most advanced in the country for degenerative and functional disease.

A unique fellowship was awarded to Babar Basir, D.O., to further last year's efforts on the Cardiogenic Shock Initiative. He is rolling out the new "gold standard" to health systems on a national and international level by sharing our experiences in the treatment of acute myocardial infarction complicated by cardiogenic shock.

The highlights of our activities and outcomes in 2017 are presented in this booklet. We acknowledge the importance of partnerships in the care of patients referred from local physicians, across the country, and around the world who allow us to move from research to recovery – all for our patients.

William W. O'Neill, M.D.
Medical Director

Center for Structural Heart Disease at Henry Ford Hospital

ACTIVITY AND OUTCOMES

Each patient who presents with a complicated case, or who has been told there are no options left has become our inspiration. Our researchers, innovators and implementers are dedicated to these patients, to move our research to recovery gives each patient the chance for a longer, healthier life.

This booklet presents the highlights for another year of dedication to our patients of the Center for Structural Heart Disease at Henry Ford Hospital. What you won't see are the entire team's countless hours and dedication that goes into research, clinical trials and late-night brainstorming over challenging cases which can only be validated by exceptional outcomes – these outcomes represent a better quality of life for the patient. To each patient who benefited from these efforts, this report is dedicated to you.

In just six years, the Center for Structural Heart Disease (CSHD) at Henry Ford Hospital has grown and is one of the top volume programs in the country delivering transcatheter aortic valve replacements (TAVR) through many approaches developed or advanced here. Transfemoral remains the most commonly performed approach. For patients who are not candidates for the femoral route, the transcaval and transcarotid approaches continue to grow in volume.

For questions regarding this report or to refer a patient, please call the Center for Structural Heart Disease at 1-855-518-5100.

CENTER FOR STRUCTURAL HEART DISEASE PROGRAM AT HENRY FORD – GROWTH

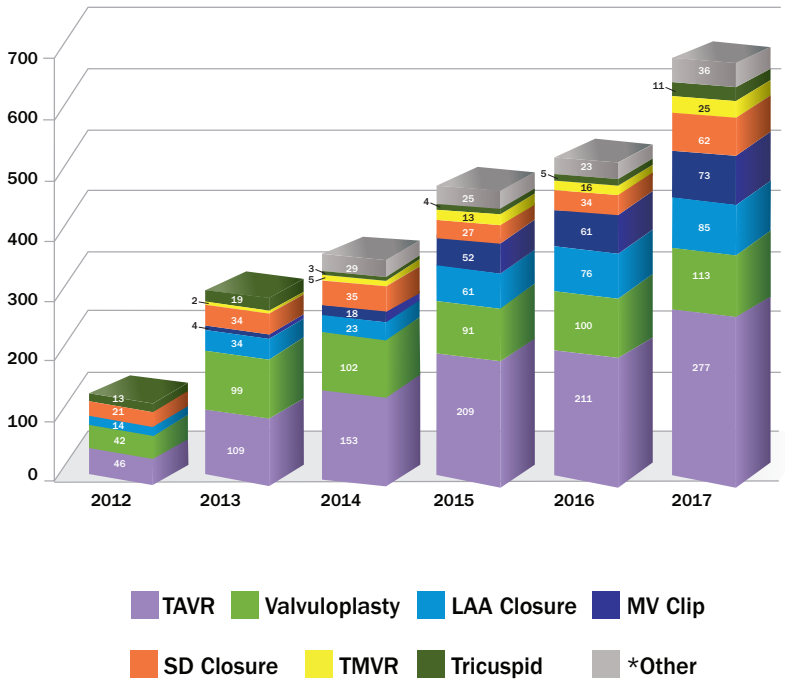

*Other: ASA, pulmonic procedures, PVL repairs

Gaetano Paone, M.D., and William W. O'Neill, M.D., with 1000th TAVR recipient, Jerry Licht

1000TH TAVR VALVE REPLACEMENT PERFORMED

The 1000th TAVR procedure, using the femoral approach, was performed by pioneering interventional cardiologist William W. O'Neill, M.D., medical director, Center for Structural Heart Disease, and Gaetano Paone, M.D., cardiothoracic surgeon, on Dec. 19, 2017 at Henry Ford Hospital. It is the first program in metro Detroit and less than 20 such programs in the United States to reach this significant milestone.

"We are honored to know we have helped so many people with advanced heart disease," said Dr. O'Neill. Tiberio Frisoli, M.D., structural heart fellow, and Trevor Szymanski, M.D., cardiovascular anesthesiologist, also assisted with the 1000th TAVR.

Severe narrowing of his aortic valve had led to progressive exhaustion for 90-year-old Jerry Licht. After the procedure, Mr. Licht, who worked in the computer industry, said he felt energy return and says he "looks forward to walking his dog and traveling more with his wife."

COMMERCIAL PROCEDURES AND DEVICES

The Center for Structural Heart Disease at Henry Ford Hospital offers the following procedures and devices:

- Transcatheter Aortic Valve Replacements (TAVR)
  - Native and dysfunctional bioprosthetic valves
  - Edwards: SAPIEN 3 Valves, Medtronic CoreValves
- Transcatheter Mitral Valve Repair (TMVR) with MitraClip® device
- Perivalvular leak repairs of prosthetic valves
- Mitral Valve Replacement (TMVR) Valve-in-Valve
  - Edwards: SAPIEN 3 Valve-in-Valve
- Left atrial appendage occlusion with Watchman™ device
- Valvuloplasty
- Patent foramen ovale, atrial and ventricular septal defect repairs

Referring physicians have the commitment of the Center for Structural Heart Disease team to return patients for follow-up care. Training to provide follow-up care in referring physician offices is also available.

HENRY FORD TAVR VOLUME GROWTH

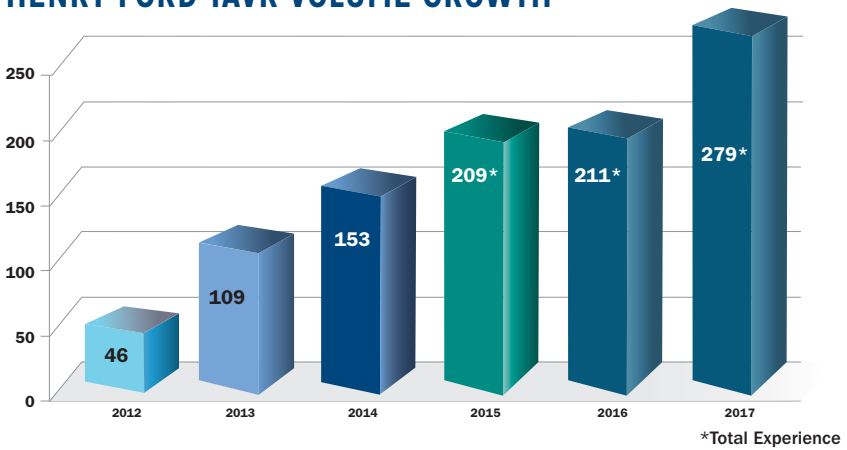

HENRY FORD TAVR 30-DAY ALL-CAUSE MORTALITY

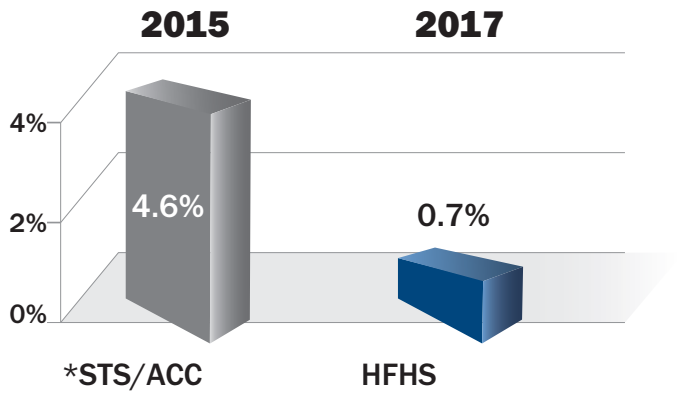

*Frederick L. Grover, MD. 2016 Annual Report of The Society of Thoracic Surgeons/American College of Cardiology Transcatheter Valve Therapy Registry. *Ann Thorac Surg. ANNUAL REPORT OF THE STS/ACC TVT REGISTRY.* 2017;103:1021–35

HENRY FORD 2015, 2016 AND 2017 TAVR VOLUMES BY APPROACH

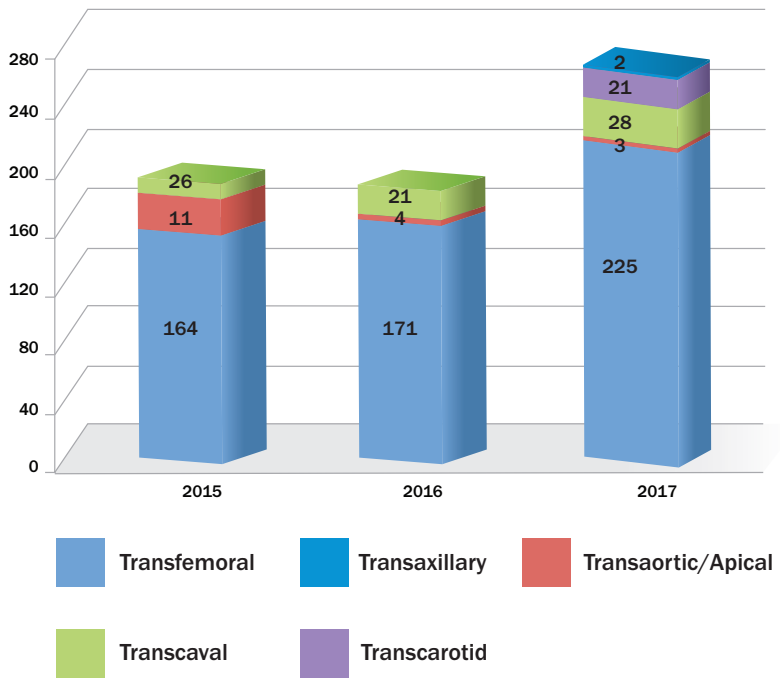

ADVANCING APPROACHES TO TAVR

Transfemoral: In the standard approach for catheterization, access is gained through the femoral vein through the groin to insert the catheter and a wire which is guided to the aorta.

Transcaval: A small incision is made where a wire is guided into a leg and up through the femoral vein and across, through the vein wall and a parallel artery in the abdomen, and then up through the artery into the heart to implant a new artificial aortic heart valve. After the valve is placed, the catheter "bridge" is removed. A plug closes the holes in the artery and the vein so the two major blood vessels can function as normal.

Transcarotid: A small incision is made in the carotid artery accessed just above the clavicle but below where the artery branches, thus safely allowing collateral blood flow to the brain. From this point, TAVR valve delivery is the same as it would be with the transfemoral approach.

Transaortic: A small incision is made in the breastbone, where the physician has access to the aorta with the catheter. From this point, TAVR valve delivery is the same as it would be with the transfemoral approach.

Transapical: A small incision is made between the ribs on the left side of the chest. A catheter is inserted through this opening to directly access the heart. From this point, TAVR valve delivery is the same as it would be with the transfemoral approach.

Transaxillary: a small incision, made near the armpit, allows the catheter to be inserted and guided to the heart to perform the TAVR procedure.

TRANSCAROTID APPROACH OFFERS ANOTHER OPTION FOR TAVR

Approximately 10 to 15 percent of patients who undergo TAVR will require non-femoral artery access. In most of these patients, valve delivery has been by either transaortic or transapical approaches, both of which require entry into the chest. To avoid a trans-thoracic procedure, physicians at Henry Ford Hospital have been using the transcarotid and transcaval approaches in those patients unsuitable for conventional transfemoral access. “We weren’t the first to use the transcarotid approach, but we were certainly one of the first to enthusiastically offer our patients this approach, after making modifications to the existing procedure,” says Gaetano Paone, M.D., cardiothoracic surgeon at Henry Ford Hospital.

“We weighed the potential complications, like stroke, that could occur when blocking the blood flow through the carotid artery on one side. Working with my Vascular Surgery colleague, Loay Kabbani, M.D., we modified the procedure to eliminate the use of shunts and monitoring devices. The carotid artery is accessed just above the clavicle, well below where the artery branches thus safely allowing collateral blood flow to the brain. From this point, TAVR valve delivery is the same as it is with a transfemoral approach. The procedure has been well tolerated and the results in almost 50 patients have been quite good, with no strokes,” explains Dr. Paone.

In a review of our recent experience with these three approaches, those patients undergoing TAVR with transcarotid and transcaval approaches had 30 day in-hospital and one-year survival similar to that of a contemporary cohort undergoing a transfemoral approach. The study suggested that avoiding surgical entry to the chest may offer procedural and intermediate term outcomes equivalent to transfemoral TAVR.

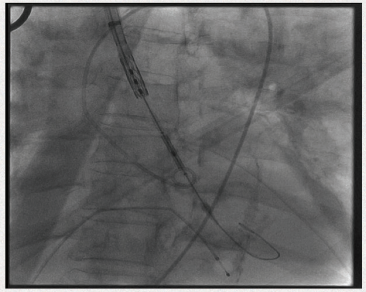

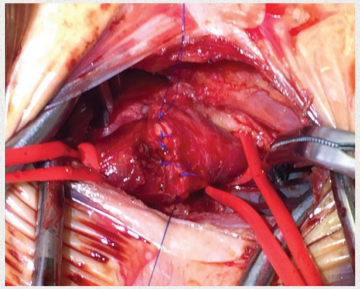

HENRY FORD VASCULAR COMPLICATION RATES VS. REPORTED 2016 AND 2017 ACTUAL

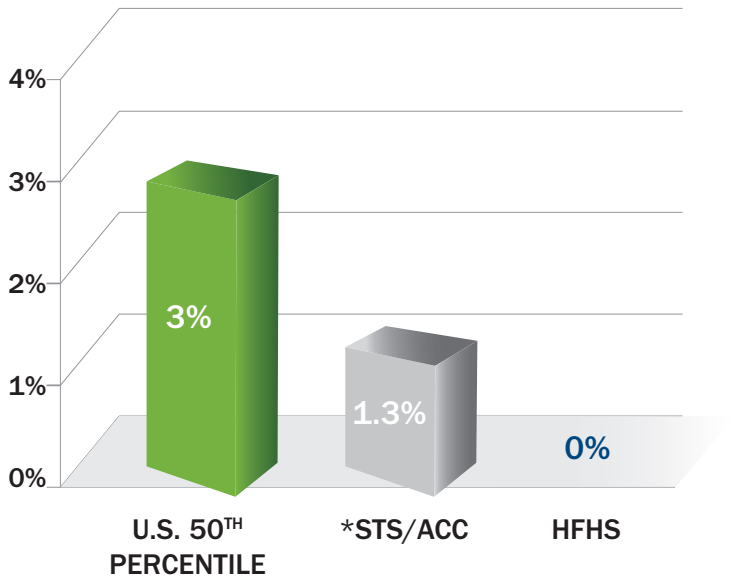

Despite the more complex, high risk cases treated in the alternate access TAVR center at Henry Ford, there have been no vascular complications.

HENRY FORD READMISSION RATES WITHIN 30 DAYS 2016 AND 2017

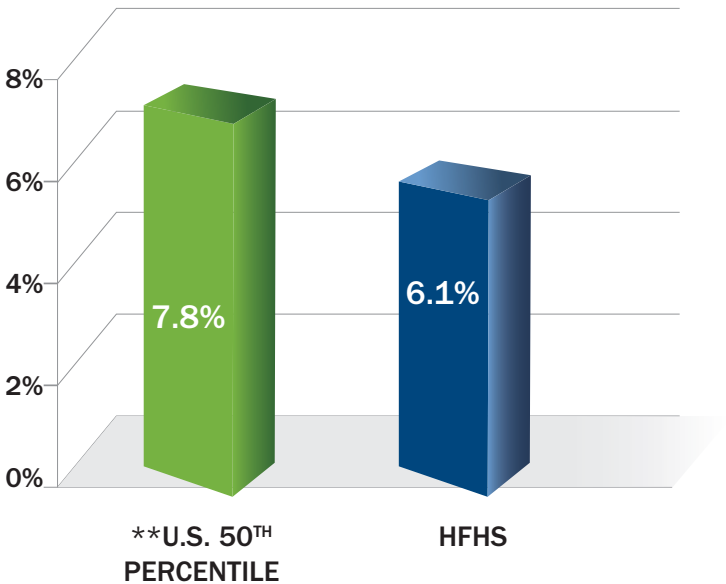

Striving always to reduce readmission rates, Henry Ford remains lower than the national readmission rates.

*Frederick L. Grover, MD. 2016 Annual Report of The Society of Thoracic Surgeons/American College of Cardiology Transcatheter Valve Therapy Registry. *Ann Thorac Surg. ANNUAL REPORT OF THE STS/ACC TVT REGISTRY.* 2017;103:1021–35

**TVT Data review continues for the last six months of 2017

MITRAL VALVE INTERVENTIONAL PORTFOLIO

The prevalence of moderate to severe mitral valvular disease in our aging population has driven the need to assemble a large portfolio of valve devices to address the anatomic complexity in both degenerative and functional mitral valve regurgitation. Marvin Eng, M.D., research director and director of the Fellowship program at the Center of Structural Heart Disease and the team of physician-researchers within Henry Ford Hospital have conducted several research studies and acquired first-hand knowledge of the effectiveness of an array of valvular solutions.



Marvin Eng, M.D.
Research Director,
Fellowship Director

Each patients' heart anatomy is unique and requires proper selection of a strategy and device for the condition or valve size. By building the largest offering of valve devices in one location, we can optimally tailor a treatment best for your patient's heart.

Mitral Regurgitation Repair

MitraClip® is used for degenerative mitral valve disease and is being investigated for functional mitral regurgitation. It has been approved for use in the United States by the FDA since 2013.

Cardioband system is in trial to evaluate performance and safety. The Cardioband Adjustable Annuloplasty System repair addresses functional mitral regurgitation, using a percutaneous transfemoral delivery system.

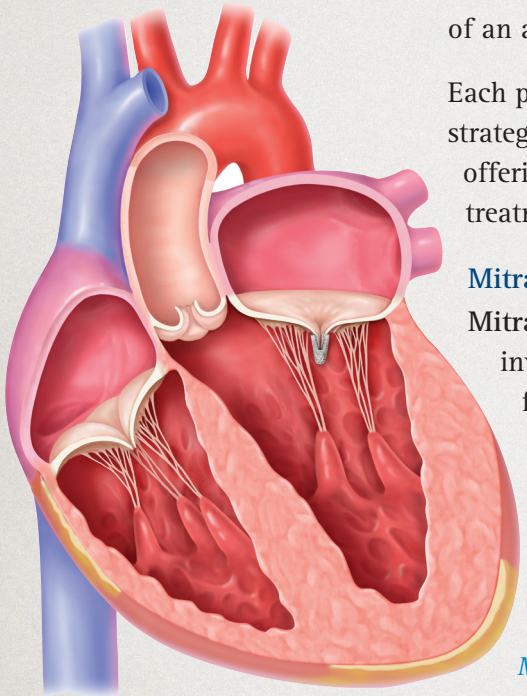

MitraClip®

Mitral Valve Replacement for Mitral Regurgitation

Tendyne is a percutaneous mitral valve replacement trial device that is implanted via a small thoracotomy and apical access. It is anchored by an apical tether and will be undergoing evaluation in a pivotal trial. There are a multitude of sizes to accommodate various patient anatomy.

Tiara, a trial device, is delivered through the apex of the heart to replace the mitral valve while preserving the integrity of the surrounding structures of the heart. (NEOVASC)

Regurgitation	Degenerative	Functional
Mitral Clip®	X	X (COAPT study)
Tendyne Valve (study)	X	X
TIARA Valve (study)	X	X
Cardioband		X

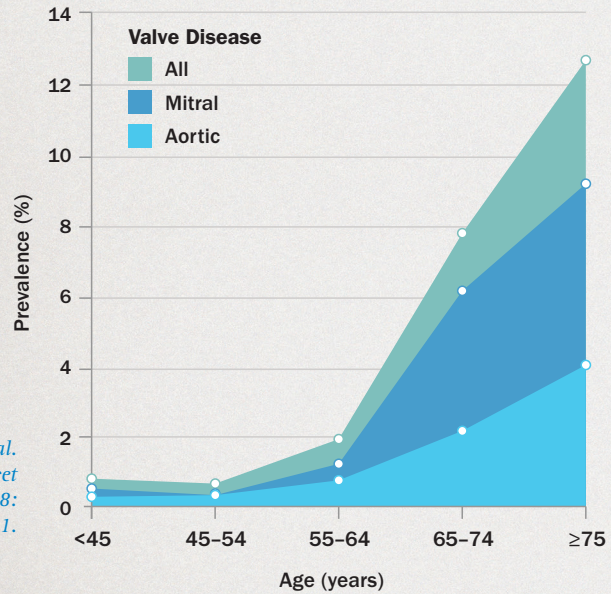

Nkomo et al. Lancet 2006;368: 1005-11.

HENRY FORD TRANSCATHETER MITRAL VALVE PROCEDURES

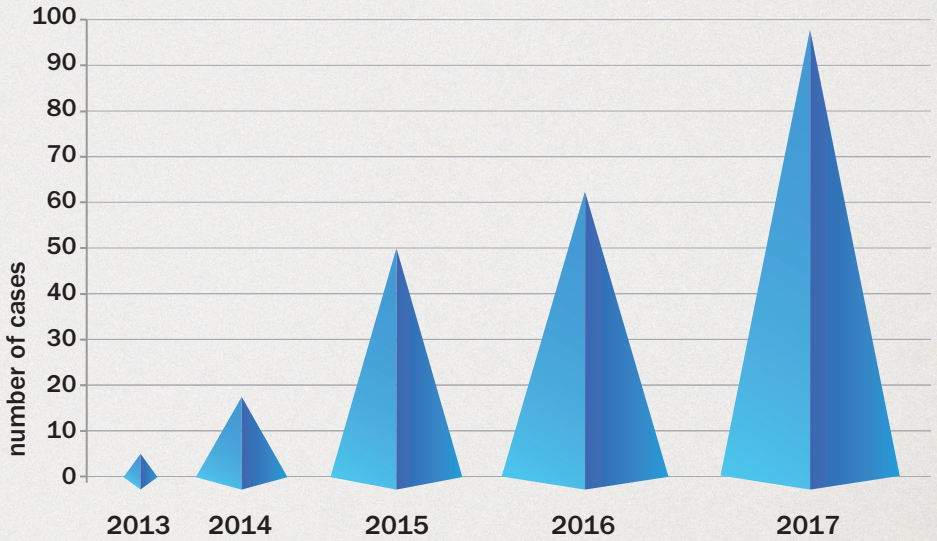

INNOVATING FOR THE RIGHT-SIDE OF THE HEART

The Center for Structural Heart Disease was asked to participate in the TRILUMINATE study. The interventional study will evaluate safety and effectiveness of the Abbott Transcatheter Clip Repair System in patients with symptomatic, moderate, severe or greater tricuspid regurgitation.

"It was our treatment using the MitraClip® device for left-side valves that garnered the request to research a treatment for tricuspid valve regurgitation," explains Adam Greenbaum, M.D., co-medical director, Center for Structural Heart Disease. "There has been very little in the way of treatment options for the right-side valves, yet data shows when multi-side valve disease is treated, patients live longer."

At this time, for those of high or prohibitive surgical risk, there are currently no FDA-approved transcatheter approaches for tricuspid valve repair. "With this study we hope to advance right-sided heart valve treatment from its infancy stage in research to where we are with left-side treatments, including use of TAVR," explains Dr. Greenbaum.

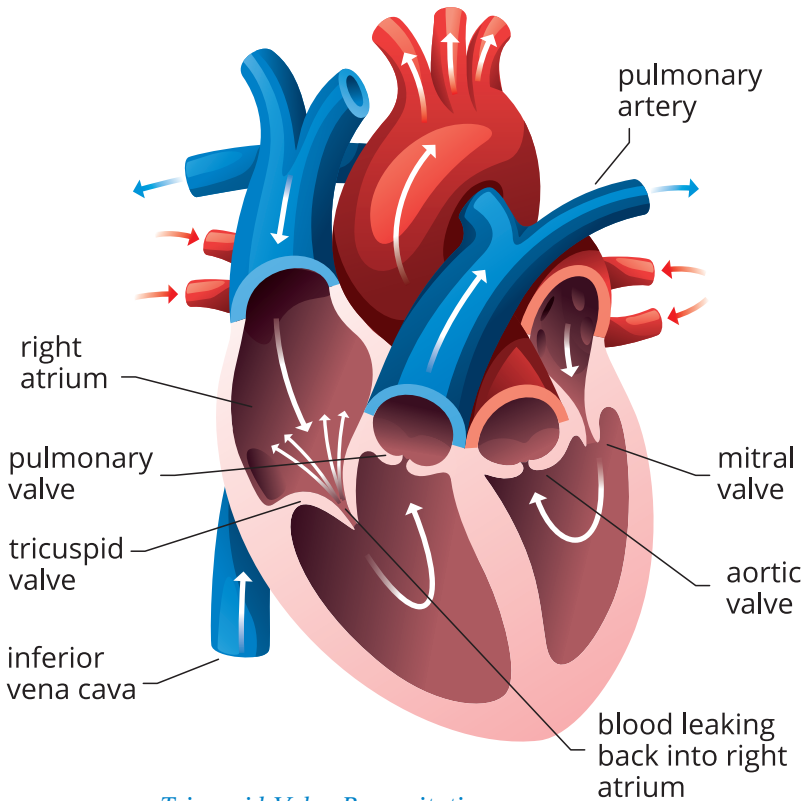

Tricuspid Valve Regurgitation

LOCAL CARDIOGENIC SHOCK INITIATIVE BECOMES A NATIONAL REGISTRY

The Cardiogenic Shock Initiative (CSI) began in July 2016. A collaborative of cardiologists in metro Detroit studied the approach of supporting the circulatory system during a STEMI, using Impella®, a straw-sized heart pump. The retrospective study demonstrated 80 percent survival rates, compared to 50 percent with traditional treatment.

The hemodynamic support protocols for treating cardiogenic shock, developed by the Detroit Cardiogenic Shock Initiative, were announced by the collaborative in a press conference in December 2017. “The best place in the country to experience cardiogenic shock is Detroit,” proclaimed Dr. O’Neill, lead researcher and medical director, Center for Structural Heart Disease.

“We saw such success in Detroit; it’s important to share this life-saving knowledge with others,” said Dr. O’Neill. In a standing-room-only crowd at the American College of Cardiology’s 2017 Scientific Sessions in Washington, D.C., Dr. O’Neill presented the hemodynamic support study. Within hours of this presentation, cardiologists from around the country contacted Henry Ford requesting to participate in the initiative.

To move the Detroit Cardiogenic Shock Initiative beyond the region onto a national platform, Babar Basir, D.O., was awarded a unique fellowship with the Center for Structural Heart Disease.

Under Dr. O’Neill’s mentorship, Dr. Basir provides education on a national and international level on the treatment of acute myocardial infarction complicated by cardiogenic shock. In October 2017, Dr. Basir presented the protocols in a standing-room-only session at the Transcatheter Cardiovascular Therapeutics (TCT) conference.

Dr. Basir and Michael Hacula, RCIS, EMT-P, coordinator of the National Cardiogenic Shock Initiative (NCSI) program, pre-screen potential organizations, those meeting the criteria receive a visit to educate and train physicians and the respective staff on the NCSI protocols and data collection for the NCSI registry. “It’s not just large academic institutions that are reaching out, but community and rural hospitals are seeking to participate. It’s exciting to see this life-saving initiative grow on a national level,” concludes Dr. O’Neill.

Henry Ford cardiologist Babar Basir, D.O., discusses the CSI with attendees from across the country.

Sunay Shah, M.D., cardiology fellow, Dee Dee Wang, M.D., and Rebecca Baumann, M.D., imaging fellow

 Ford Motor Company Fund supports Henry Ford Hospital in its development of 3D Guided Imaging.

PREDICTION MODELING VALIDATED TO PREVENT LVOT

Mitral valve disease is the most common type of valvular heart disease in the United States in patients over the age of 55. Age combined with multiple comorbidities and prior sternotomies elevate the risk of mortality to 7.4 to 15.1 percent during mitral valve replacement in this population.

"The importance of being able to identify patients who are suitable candidates for transcatheter mitral therapies was highlighted by this study," said Dee Dee Wang, M.D., director of Center for Structural Heart Disease Interventional Imaging at Henry Ford Hospital.

Unlike the straightforward transcatheter treatment of the aortic valve, the mitral valve is a complex anatomical structure. Percutaneous prosthetic valve implantation at the mitral position for degenerated native, repaired, or prosthetic mitral valves is a burgeoning technique, but can be complicated or fatal when a left ventricular outflow tract (LVOT) obstruction occurs.

As the lead researcher, Dr. Wang and her colleagues set out to demonstrate proof-of-concept that computed tomography (CT) computer-aided design (CAD) prediction modeling tools would correctly identify patients who were at risk for LVOT obstruction in transcatheter mitral valve replacement (TMVR).

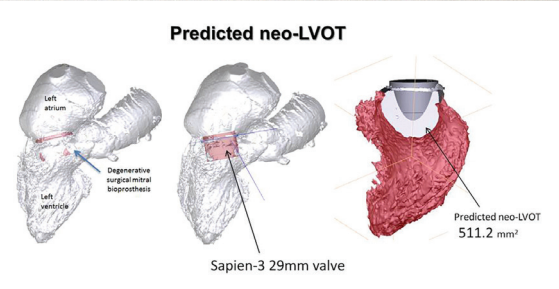

The concept of patient-specific anatomical screening and LVOT modeling for TMVR demonstrated the utility of cardiac CT and ex vivo transcatheter heart valve (THV) fit testing with 3D models to predict LVOT obstruction in TMVR. Thus, validating CAD design and CT post-processing are indispensable tools in predicting LVOT obstruction and necessary for anatomic screening in percutaneous TMVR.

Note: The complete study is available:

***Wang DD, Eng MH, Greenbaum AB**, Myers E, Forbes M, Barabon P, Pantelic M, Song T, Nadig J, **Guerrero M, O'Neill WW**. Validating a prediction modeling tool for left ventricular outflow tract (LVOT) obstruction after transcatheter mitral valve replacement (TMVR). Catheter Cardiovasc Interv. 2017 Dec 11. doi: 10.1002/ccd.27447.*

Dr. William W. O'Neill explains to patient Eric Hurttgam the procedure using a 3D model of his own heart.

From Research to Recovery

3D GUIDED IMAGING: PREDICT AND PREVENT VALVE PLACEMENT RISK

Since 2013, the lives of 1,000 patients have been improved through the use of 3D guided imaging for the planning and guidance of transcatheter heart valve replacements or repair. "With 3D computer-aided design technology and advanced 3D imaging we have the opportunity to provide personalized procedure plans for our high-risk patients who have been otherwise turned down for traditional open-heart surgery," says Dee Dee Wang, M.D., director, Structural Interventional Imaging, Henry Ford Hospital.

Henry Ford cardiology is helping transform the field of 3D imaging and 3D printing through the leadership and vision of William W. O'Neill, M.D., director of the

Center for Structural Heart Disease program, and the support of Henry Kim, M.D., chair of cardiology and Scott Dulchavsky, M.D., chair of surgery.

For the past five years, Dr. O'Neill and his team have been pioneering new valve technologies to help patients with mitral valve disease. However, not all new valve technologies are a match for each patient's specific heart anatomy. Subtle details in how these new devices are sized and placed can lead to complications such as valve embolization, leaking around the valve, and left ventricular outflow tract (LVOT) obstruction. With the use of multi-modality imaging, the team thinks outside-the-box to find ways to treat these diseases non-surgically.

A partnership with the Henry Ford Innovation Institute, led by Dr. Wang with her team: Marianne Rollet, Eric Myers, Michael Forbes and Tongwa Aka, multiple publications have been written, and a patented planning tool to identify patients best suited for high risk transcatheter mitral valve replacement procedures was developed. Using advanced CT technology, virtual valves are meticulously sized and virtually fit tested at different implantation depths and angles. This data is then computer-simulated in a virtual model to anticipate any complications or risks associated with the procedure. In the end, a 3D printed model helps to guide the individual patient's procedure.

Predicating LVOT obstruction after TMVR, published in *Cardiovascular Imaging*, provides clinical evidence of the importance of using 3D virtual valves. Dr. Wang explained, "This study offers new insight into safely performing these complex procedures. It's a significant advancement in the use of 3D imaging that allows the Henry Ford Structural Heart Disease team to personalize treatment plans and procedures specific to each patient's body."

Planning with the use of advanced computer-aided design 3D technology, imaging and 3D printing has changed the way cardiologists on the Henry Ford Structural Heart Disease team practice medicine.

Acknowledgements: Funding for this research made possible through generosity of the Ford Motor Company Fund.

Note: The complete study is available:

***Wang, DD**, et al. (Vol. 9, No. 11, 2016). JACC: Cardiovascular Imaging. Predicating LVOT Obstruction After TMVR.*

BASILICA AND LAMPOON PROCEDURES SHOW PROMISE

Yet another new heart valve procedure may offer hope to many patients with aortic valve disease, who have been told they're out of options.

The acronym BASILICA stands for Bioprosthetic Aortic Scallop Intentional Laceration to prevent Iatrogenic Coronary Artery obstruction. The BASILICA procedure is used during an aortic valve replacement, or TAVR (Transcatheter Aortic Valve Replacement). For TAVR, a catheter is placed inside the heart and a balloon is used to open a new valve inside the native aortic valve.

In some patients with particular anatomy, the native valve's leaflets block the flow of blood to the coronary arteries as the new valve's scaffolding opens. The complication is fatal unless corrected and is prevented during traditional open heart surgery by cutting away the native valve itself.

The BASILICA procedure solves this issue during TAVR. The cardiologist weaves an electrified wire the size of a sewing thread through a catheter and uses it to slice the patient's native aortic leaflet. The slice prevents the flap from blocking critical blood flow through the heart when the doctor deploys the new valve.

Adam Greenbaum, M.D., co-director of the Center for Structural Heart disease, says "The BASILICA procedure is a potentially life-saving development in cardiology." He helped develop the procedure with Danny Dvir, M.D., at the University of Washington in Seattle; Vasilis Babaliaros, M.D., at Emory University in Atlanta; and Robert Lederman, M.D., and Jaffar Khan, BM BCh, of the National Institutes of Health.

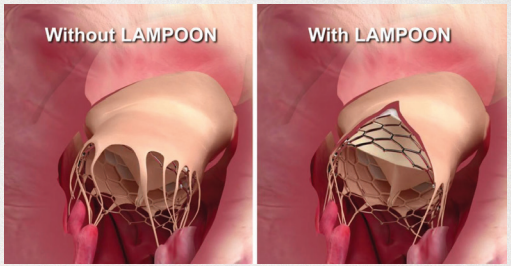

Courtesy of the National Institutes of Health

This slicing of a heart valve leaflet was first performed in man for similar issues in a mitral valve is called LAMPOON, or 'Laceration of the Anterior Mitral valve leaflet to Prevent Outflow track ObstructioN. Of the more than 30 procedures performed about half were performed at Henry Ford Hospital, another 30 at Emory University in Atlanta.

"Both of these procedures are in their infancy but show exciting promise," Dr. Greenbaum said. "It's gratifying to develop and share advances in medicine that can save lives across the United States."

ACTIVE ENROLLMENT RESEARCH PROTOCOLS

AMPLATZER™ Amulet™ LAA Occluder Trial (Amulet IDE) - The Amulet™ device will be evaluated for safety and efficacy by demonstrating non-inferiority to the commercially available WATCHMAN™ left atrial appendage closure device in patients with non-valvular atrial fibrillation.

The PARTNER 3 – Trials - To establish the safety and effectiveness of the Edwards SAPIEN 3 Transcatheter Heart Valve in patients with severe, calcific aortic stenosis or failing bio-prosthetic valve who are at low operative risk for standard aortic valve replacement.

Early TAVR - To establish the safety and effectiveness of the Edwards SAPIEN 3 Valve compared with clinical surveillance in asymptomatic patients with severe, calcific aortic stenosis.

LAMPOON - Closed chest transcatheter laceration of the anterior mitral leaflet to prevent LVOT obstruction during Transcatheter Mitral Valve Replacement.

TENDYNE Trial - Early feasibility study of the Tendyne Mitral Valve System in adult patients with symptomatic mitral regurgitation who are not suitable candidates for conventional mitral valve repair or replacement.

TIARA - To evaluate the safety and initial performance of the Neovasc Tiara Mitral Transcatheter Heart valve with the Tiara Transapical Delivery System.

Mitral Implantation of TRAnscatheter vaLves (MITRAL) - Establish the safety and feasibility of the Edwards SAPIEN XT and SAPIEN 3 device and systems in patients with severe symptomatic calcific mitral valve disease with severe mitral annular calcification who are not candidates for standard mitral valve surgery.

COAPT Clinical Trial (COAPT) - Assess safety and effectiveness of MitraClip™ system for the treatment of moderate to severe functional mitral regurgitation deemed not appropriate for surgery.

For Dennis Stora, it was the use of plastic models, printed in the 3D print lab that eventually identified exactly where Stora's defect was and which surgical approach was best for him.

CENTER FOR STRUCTURAL HEART DISEASE PUBLICATION LIST

2018

Eng, MH, Wang DD, Greenbaum AB, Gheewala N, Kupsky D, Aka T, Song T, Kendall BJ, Wyman J, Myers E, Forbes M, **O'Neill WW.** Prospective, randomized comparison of 3-dimensional computed tomography guidance versus TEE data for left atrial appendage occlusion (PRO3DLAAO). *Catheter Cardiovasc Interv.* 2018 Feb 1 doi: 10.1002/ccd.27514.

2017

Guerrero M, Wang DD, O'Neill WW. Percutaneous Rescue of an Embolized Valve After Transcatheter Mitral Valve Replacement. *JACC Cardiovasc Interv.* 2017 Mar 27;10(6):627-629. doi: 10.1016/j.jcin.2017.01.020.

Singh V, Yadav PK, **Eng MH,** Macedo FY, Silva GV, Mendirichaga R, Badiye AP, Sakhuja R, Elmariah S. Outcomes of hemodynamic support with Impella in very high-risk patients undergoing balloon aortic valvuloplasty: Results from the Global cVAD Registry. *Int J Cardiol 2017.* Aug 1;240:120-125. doi: 10.1016/j.ijcard.2017.03.071. Epub 2017 Mar22.

Wang DD, Eng MH, Greenbaum AB, Myers E, Forbes M, Barabon P, Pantelic M, Song T, Nadig J, **Guerrero M, O'Neill WW.** Validating a prediction modeling tool for left ventricular outflow tract (LVOT) obstruction after transcatheter mitral valve replacement (TMVR). *Catheter Cardiovasc Interv.* 2017 Dec 11. doi: 10.1002/ccd.27447

Greenbaum AB, Frisoli TM. Surgical Paravalvular Leak Closure: No More Second Chances. *JACC Cardiovasc Interv.* 2017 Mar 13;10(5):508-509. doi: 10.1016/j.jcin.2017.01.031.

Kamioka N, Patel A, Burke MA, **Greenbaum AB,** Babaliaros V. Biventricular Impella placement via complete venous access. *Catheter Cardiovasc Interv.* 2017 May 22. doi: 10.1002/ccd.27103. [Epub ahead of print]

CENTER FOR STRUCTURAL HEART DISEASE PUBLICATION LIST

Babaliaros VC, **Greenbaum AB**, Khan JM, Rogers T, **Wang DD**, **Eng MH**, **O'Neill WW**, **Paone G**, Thourani VH, Lerakis S, Kim DW, Chen MY, Lederman RJ. Intentional Percutaneous Laceration of the Anterior Mitral Leaflet to Prevent Outflow Obstruction During Transcatheter Mitral Valve Replacement: First-in-Human Experience. *JACC Cardiovasc Interv.* 2017 Apr 24;10(8):798-809. doi: 10.1016/j.jcin.2017.01.035.

Basir MB, Schreiber TL, Grines CL, Dixon SR, Moses JW, Maini BS, **Khandelwal AK**, Ohman EM, **O'Neill WW**. Effect of early initiation of mechanical circulatory support on survival in cardiogenic shock. *Am J Cardiol.* 2017 Mar 15;119(6):845-851. doi: 10.1016/j.amjcard.2016.11.037.

Eng MH, **Greenbaum AB**, **Wang DD**, **Wyman J**, Dnp, Arjomand H, Yadav P, **Nemeh HW**, **Paone G**, **Guerrero M**, **O'Neill WW**. Thrombotic valvular dysfunction with transcatheter mitral interventions for postsurgical failures. *Catheter Cardiovasc Interv.* 2017 Aug 1;90(2):321-328. doi: 10.1002/ccd.26909. Epub 2017 Feb 10.

Frisoli TM, **Wang DD**, **Eng MH**, **O'Neill WW**, **Paone G**, **Greenbaum AB**. Mitral Annuloplasty Ring Fracture and Annular Injury During Transcatheter Mitral Valve-in-Ring Intervention. *JACC Cardiovasc Interv.* 2017 Oct 9;10(19):e181-e184. doi: 10.1016/j.jcin.2017.09.005.

Goodwin M, **Nemeh HW**, **Borgi J**, **Paone G**, Morgan J. Resolution of Mitral Regurgitation With Left Ventricular Assist Device Support. *The Annals of Thoracic Surgery.* 2017, Sept, 104, (3), 811-818.

Khan JM, Rogers T, Schenke WH, **Greenbaum AB**, Babaliaros VC, **Paone G**, Ramasawmy R, Chen MY, Herzka DA, Lederman RJ. Transcatheter pledget-assisted suture tricuspid annuloplasty (PASTA) to create a double-orifice valve. *Catheter Cardiovasc Interv.* 2018 Feb 6. doi: 10.102/ccd.27531.

Greenbaum AB, Condado JF, **Eng MH**, Lerakis S, **Wang DD**, Kim DW, Lederman RJ, **Paone G**, **O'Neill WW**, Thourani VH, Babaliaros VC. Long or redundant leaflet complicating transcatheter mitral valve replacement: Case vignettes that advocate for removal or reduction of the anterior mitral leaflet. *Catheter Cardiovasc Interv.* 2017 May 4. doi: 10.1002/ccd.27054. [Epub ahead of print]

Guerrero M, **Wang DD**, Himbert D, Urena M, Pursnani A, Kaddissi G, Iyer V, Salinger M, Chakravarty T, **Greenbaum AB**, Makkar R, Vahanian A, Feldman T, **O'Neill WW**. Short-term results of alcohol septal ablation as a bail-out strategy to treat severe left ventricular outflow tract obstruction after transcatheter mitral valve replacement in patients with severe mitral annular calcification. *Catheter Cardiovasc Interv.* 2017 Mar 7. doi: 10.1002/ccd.26975. [Epub ahead of print]

Hansen JW, Foy A, Yadav P, Gilchrist IC, Kozak M, Stebbins A, Matsouaka R, Vemulapalli S, Wang A, **Wang DD**, **Eng MH**, **Greenbaum AB**, **O'Neill WW**. Death and Dialysis After Transcatheter Aortic Valve Replacement: An Analysis of the STS/ACC TVT Registry. *JACC Cardiovasc Interv.* 2017 Oct 23;10(20):2064-2075. doi: 10.1016/j.jcin.2017.09.001.

Greenbaum AB, Babaliaros VC, Chen MY, Stine AM, Rogers T, **O'Neill WW**, **Paone G**, Thourani VH, Muhammad KI, Leonardi RA, Ramee S, Troendle JF, Lederman RJ. Transcaval Access and Closure for Transcatheter Aortic Valve Replacement: A Prospective Investigation. *J Am Coll Cardiol.* 2017 Feb 7;69(5):511-521. doi: 10.1016/j.jacc.2016.10.024.

Khan JM, Rogers T, **Eng MH**, Lederman RJ, **Greenbaum AB**. Guidewire electrosurgery-assisted trans-septal puncture. *Catheter Cardiovasc Interv.* 2017 Sep 20. doi: 10.1002/ccd.27311. [Epub ahead of print]

CENTER FOR STRUCTURAL HEART DISEASE PUBLICATION LIST

Kolte D, Khera S, Sardar MR, Gheewala N, Gupta T, Chatterjee S, Goldsweig A, Aronow WS, Fonarow GC, Bhatt DL, **Greenbaum AB**, Gordon PC, Sharaf B, Abbott JD. Thirty-Day Readmissions After Transcatheter Aortic Valve Replacement in the United States: Insights From the Nationwide Readmissions Database. *Circ Cardiovasc Interv.* 2017 Jan;10(1). pii: e004472. doi: 10.1161/CIRCINTERVENTIONS.116.004472.

Lederman RJ, **Greenbaum AB**, Rogers T, Khan JM, Fusari M, Chen MY. Anatomic Suitability for Transcaval Access Based on Computed Tomography. *JACC Cardiovasc Interv.* 2017 Jan 9;10(1):1-10. doi: 10.1016/j.jcin.2016.09.002.

Yadav P, **Wang DD, Eng MH, O'Neill WW.** Watchman in ascending aorta for systemic protection (WAASP): novel use of watchman in ascending aorta for embolic protection-first in man. *Cardiovas Interv.* 2017 May 4. doi: 10.1002/ccd.27117.

Vikas S, Yadav PK, **Eng MH**, Macedo FY, Silva GV, Mendirichaga R, Badiye AP, Sakhuja R, Elmariah S, Inglessis I, Alfonso CE, Schreiber TL, Cohen M, Palacios I, **O'Neill WW**. Outcomes of hemodynamic support with Impella in very high-risk patients undergoing balloon aortic valvuloplasty: Results from the Global cVAD Registry. *International Journal of Cardiology.* 2017, Aug, 1, 240 120-125. doi: http://dx.doi.org/10.1016/j.ijcard.2017.03.071.

Yadav P, **Eng MH.** Power of gradients. *Catheter Cardiovasc Interv.* 2017 Dec 1:90(7):1183-1184. doi:10.1002/ccd.27435.

STRUCTURAL HEART PROGRAM FOR REFERRING PHYSICIANS

Meet Kristin Sexton, RN, Outreach Coordinator. Kristin is available to assist physicians who choose to refer patients to the Center for Structural Heart Disease at Henry Ford Hospital in Detroit. Contact Kristin directly with questions about the program or to connect with one of the physicians.

Kristin can assist with facilitating outpatient consultations, inpatient transfers, enrolling patients into a clinical trial and can also assist physicians who are interested in observing procedures at Henry Ford Hospital. Kristin will arrange for concierge services for referred patients and helps with guest housing for patients who will require an inpatient stay.

Kristin Sexton, RN, BSN
Outreach Coordinator
Center for Structural Heart Disease

Cell Phone: (313) 347-3604
Email: ksexton9@hfhs.org

For more information, visit:
henryford.com/structuralheart

Kristin Sexton, RN, BSN
Outreach Coordinator

CENTER FOR STRUCTURAL HEART DISEASE TEAM

William W. O'Neill, M.D.
Medical Director



Adam Greenbaum, M.D.
Co-Director



Marvin Eng, M.D.
Research Director
Fellowship Director



Dee Dee Wang, M.D.
Director, Structural Heart Imaging



Gaetano Paone, M.D.
Division Head, Cardiac Surgery

Hassan W. Nemeh, M.D.
Surgical Director, Heart and Lung Transplant



Tiberio Frisoli, M.D.
Structural Heart Cardiologist

Dimitrios Apostolou, M.D.
Cardiothoracic Surgery, Transplant Surgery



James C. Lee M.D.
Advanced Structural Imaging



Michael Isley, M.D.
Cardiac Anesthesiologist



Trevor Szymanski, M.D.
Cardiac Anesthesiologist

Janet Wyman, DNP, RN-CS
Clinical Manager

Henry Ford Heart & Vascular Institute
Center For Structural Heart Disease

For more information, visit: henryford.com/structuralheart
1-855-518-5100

Henry Ford Health System®

all for you